



---

## Meconium stained amniotic fluid as a clinical marker for neonatal outcomes

Nancy Mohamed Ali Rund<sup>1\*</sup>, Mahmoud Fathy Hassan<sup>2</sup>

<sup>1</sup> Obstetrics and Gynecology Department, Faculty of Medicine; Ain Shams University. Cairo, Egypt

---

### Abstract

**Background:** Meconium characterized by being sticky dark-green in nature composed of gastrointestinal secretions besides various cellular debris and amniotic fluid that accumulate within the fetal gastro intestinal system that reflect the maturation of fetal gastrointestinal activity.

**Aim:** to investigate obstetric clinical outcomes in meconium stained amniotic fluid cases comparing between thin and thick meconium.

**Methodology:** A clinical research case-control trial investigating meconium stained amniotic fluid, with clinical value as regards early maternal and neonatal wellbeing aspects conducted by recruitment 200 research study subjects having meconium stained amniotic fluid with additional 100 research study subjects having clear amniotic fluid as research control group.

**Results:** There was no statistically significant difference between both research groups as regards O<sub>2</sub> supplementation endotracheal intubation, ventilator support, antibiotics, inotropes, screen positive, culture positive (p values =0.077, 0.580, 0.841, 0.390, 0.277, 0.157, 0.391 consecutively). Whereas neonatal death was statistically significantly higher among meconium stained cases research group (p value=0.032). Thick meconium was associated with more abnormal fetal heart rate pattern in a statistically significant manner (p value<0.001).

**Conclusions:** This research study revealed the critical importance of meconium heavy staining of amniotic fluid to abnormal fetal heart rate denoting that it could be implemented as clinical predictability tool for fetal distress even in absence of fetal monitoring, however future research efforts are required to be multicentric in fashion with larger sample sizes to verify our study results.

**Keywords:** meconium stained, amniotic fluid, marker

---

### Introduction

Meconium characterized by being sticky dark-green in nature composed of gastrointestinal secretions besides various cellular debris and amniotic fluid that accumulate within the fetal gastro intestinal system that reflect the maturation of fetal gastrointestinal activity <sup>[1, 2]</sup>.

However, passage of meconium has been an issue of concern since its passage could reflect fetal distress issues that could predict unfavorable neonatal outcomes such as meconium aspiration syndrome. Meconium aspiration syndrome is considered one of the neonatal emergencies requiring immediate airway suction and clearance besides antibiotic administration to prevent any morbid neonatal sequelae. Meconium aspiration syndrome issues are commonly observed in postdate gestations or in IUGR fetuses <sup>[3, 4]</sup>. A raised incidence level of meconium passage within the amniotic cavity is observed in existence of fetomaternal distress factors e.g. hypoxia and infection, despite the stage of fetal maturity. On the other hand, artificial rupture of membranes that would reflect the color of amniotic fluid is one of the commonly performed obstetric interventions within the labor ward to accelerate the physiological process of labor however it could occur in a spontaneous manner <sup>[5, 6]</sup>. Furthermore, the clearer the amniotic fluid the more the obstetrician considers this a reassuring sign as regards fetal wellbeing, however even lightly meconium stained amniotic

fluid is considered reassuring as long as the fetal monitoring shows no fetal distress aspects such as fetal variable decelerations <sup>[7, 8]</sup>. However, the appearance of thick meconium staining is critical scenario that denotes an alarming fetal distress that requires a speedy delivery and neonatal care to avoid meconium aspiration issues. Neonatal researchers have demonstrated that meconium stained amniotic fluid is a critical fetal compromise sign correlated to raised perinatal morbidity and mortality levels in which it was observed that around 5% of neonates born having meconium stained amniotic fluid develop meconium aspiration syndrome <sup>[9, 10]</sup>. Prior research groups of investigators in various research studies have revealed and displayed that the passage of meconium reflects that the oxygen saturation levels within the umbilical vein is at or under 30%. That research finding could be justified by the fact that anoxia weakens the activity levels of rectal sphincters causing subsequently meconium passage. Previous research studies have clearly revealed that placental insufficiency, pre-eclampsia, or maternal drug abuse could also cause meconium intrauterine passage <sup>[11, 12]</sup>.

### Aim of this study

Was to investigate obstetrical clinical outcomes in meconium stained amniotic fluid cases and comparing between the passage of thin and thick meconium.

### Methodology

This clinical case-control study was carried out in Saudi Arabia, in Jeddah at a private hospital (Bugshan Hospital) for a period starting from March 2016 to March 2018. The research was conducted in a prospective manner on 200 cases having meconium stained amniotic fluid with additional 100 research study subjects having clear amniotic fluid as research control group. All the patients were provided with an informed consent after receiving a full explanation of the nature and protocol of the study. Inclusive research criteria involved the following Singleton, full term, vertex presentation, living gestation with meconium staining of amniotic fluid observed after membranes rupture for cases and clear amniotic fluid for control research group. All research study subjects' cases and controls have been subjected to full clinical history, examination and fetal monitoring with emphasis on neonatal and maternal clinical outcomes (e.g. mode of delivery, requirement of ventilation and intubation)

### Statistical Analysis

Data were collected, revised, coded and entered to the Statistical Package for Social Science version 23 (IBM SPSS Ver. 23).

Qualitative data were presented as numbers and percentages and compared between groups using Chi-square test and/or Fisher exact test only when the expected count in any cell found less than 5. Also, quantitative data were presented as means and standard deviations when parametric and compared using Independent t-test.

The confidence interval was set to 95% and the margin of error accepted was set to 5%. So, the p-value was considered significant at the level of  $< 0.05$ .

### Results

Table (1) reveals and displays the demographic data, high risk conditions, fetal heart rate and mode of delivery between the two investigated research groups in which there was no statistically significant difference as regards maternal age, gestational age, fetal weight (p values =0.101, 0.387, 0.232 consecutively). Whereas there was highly statistically significant difference as regards presence of anemia, abnormal fetal heart rate patterns, LSCS and assisted vaginal delivery being higher among meconium stained cases research group (p values  $< 0.001$ ). Furthermore, postdate pregnancies were statistically significantly higher among cases research groups (p value=0.036).

**Table 1:** Demographic data, high risk conditions, fetal heart rate and mode of delivery between the two studied groups

	Cases No. = 200	Controls No. = 100	Test value	P-value	Sig.
Maternal age	28.29 ± 6.65	29.68 ± 7.36	1.646*	0.101	NS
Gestational age (weeks)	38.83 ± 3.27	39.15 ± 2.43	0.866*	0.387	NS
Fetal weight (gm)	3284.25 ± 215.3	3321.42 ± 315.74	1.199*	0.232	NS
High risk conditions					
Anemia	80 (40.0%)	65 (65.0%)	16.685*	<0.001	HS
Moderate	57 (71.3%)	43 (66.2%)	0.435*	0.509	NS
Severe	23 (28.8%)	22 (33.85%)			
PIH	42 (21.0%)	13 (13.0%)	2.850*	0.091	NS
Mild	31 (73.8%)	10 (76.9%)	0.208*	0.648	NS
Severe	11 (26.2%)	3 (23.1%)			
Eclampsia	5 (2.5%)	2 (2.0%)	0.073*	0.787	NS
Pregnancy > 40 weeks	31 (15.5%)	7 (7.0%)	4.354*	0.036	S
Prom	9 (4.5%)	3 (3.0%)	0.391*	0.531	NS
Oligohydramnios	13 (6.5%)	4 (4.0%)	0.779*	0.377	NS
IUGR	5 (10.0%)	4 (4.0%)	0.515*	0.472	NS
Prev CS	15 (7.5%)	7 (7.0%)	0.025*	0.874	NS
Abruptio placenta	5 (2.5%)	2 (2.0%)	0.073*	0.787	NS
Fetal Heart pattern			25.276*	<0.001	HS
Normal baseline FHR	117 (68.5%)	87 (87.0%)			
Outside normal baseline FHR	61 (30.5%)	11 (11.0%)			
Variable FHR	22 (11.0%)	2 (2.0%)			
Mode of delivery			23.118*	<0.001	HS
Find	62 (31.0%)	58 (58.0%)			
LSCS	120 (60.0%)	32 (32.0%)			
Vacuum	8 (4.0%)	3 (3.0%)			
Forceps	10 (5.0%)	7 (7.0%)			

\*: Chi-square test; \*: Independent t-test

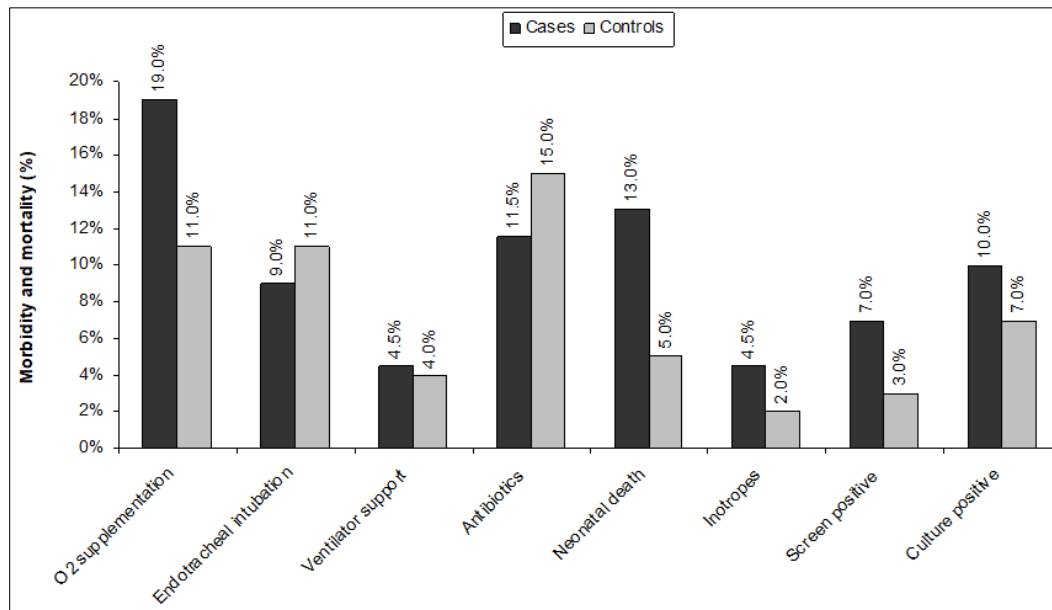
Table (2) and figure (1) reveals and displays that there was no statistically significant difference between both research groups as regards O<sub>2</sub> supplementation endotracheal intubation, ventilator support, antibiotics, inotropes, screen positive, culture

positive (p values =0.077, 0.580, 0.841, 0.390, 0.277, 0.157, 0.391 consecutively). Whereas, the neonatal death was statistically significantly higher among meconium stained cases research group (p value=0.032).

**Table 2:** Morbidity and mortality of the two studied groups

	Cases No. = 200	Controls No. = 100	Test value*	P-value	Sig.
O2 supplementation	38 (19%)	11 (11.0%)	3.122	0.077	NS
Endotracheal intubation	18 (9.0%)	11 (11.0%)	0.305	0.580	NS
Ventilator support	9 (4.5%)	4 (4.0%)	0.040	0.841	NS
Antibiotics	23 (11.5%)	15 (15.0%)	0.738	0.390	NS
Neonatal death	26 (13.0%)	5 (5.0%)	4.605	0.032	S
Inotropes	9 (4.5%)	2 (2.0%)	1.180	0.277	NS
Screen positive	14 (7.0%)	3 (3.0%)	1.995	0.157	NS
Culture positive	20 (10.0%)	7 (7.0%)	0.733	0.391	NS

\*: Chi-square test



**Fig 1:** Morbidity and mortality of the two investigated research groups

Table (3) reveals and displays the correlation between meconium and fetal heart rate in which thick meconium was associated with more abnormal fetal heart rate pattern in a statistically significant manner (p value<0.001)

**Table 3:** Relation between meconium and fetal heart rate

	Thin	Thick	Test value*	P-value	Sig.
	No. = 110	No. = 90			
Alone	95 (86.4%)	15 (16.7%)	97.153	<0.001	HS
With abnormal FHR pattern	15 (13.6%)	75 (83.3%)			

\*: Chi-square test

**Discussion**

Clinical assessment of meconium stained amniotic fluid cases is crucial since heavily stained amniotic fluid could denote the presence of severe fetal hypoxic issues that have its long-term sequelae. Careful intrapartum fetal heart rate electronic monitoring is one of the cornerstone safety measures that could in conjunction to clinical signs could safe guard the fetal hypoxia when prompt diagnosis is made intrapartum. Airway management is critical to be conducted immediately, requirement for suction and intubation have to be based upon neonatal state not only meconium presence. Meconium stained amniotic fluid is considered as a predictability clinical tool of maternal and perinatal complications [13, 14]. A prior research group of

investigators have revealed and displayed that thick or thin meconium are reflective of fetal distress. Investigators compared the pregnancy clinical outcomes in deliveries complicated by primary meconium stained amniotic fluid and secondary meconium stained amniotic fluid (converted from clear to meconium stained amniotic fluid during the process of labor). They observed among their research findings that the secondary meconium stained amniotic fluid research group had a statistically higher cesarean section delivery rates and vaginal assisted deliveries. Denoting that higher rates of adverse neonatal clinical outcomes, cesarean section deliveries, and assisted vaginal deliveries, are present in secondary in comparison to primary meconium stained amniotic fluid [1, 3, 5].

Prior research studies have displayed that the meconium stained amniotic fluid existence could be a reflection of fetal maturity status and not only as a clinical marker mirroring fetal distress another prior research team of investigators have shown that early heavy meconium stained amniotic fluid is correlated to raised fetal and neonatal morbidity and mortality issues, on the other hand the “late passage of meconium stained amniotic fluid” didn’t show significant perinatal losses, however it has been correlated to raised neonatal morbidity that occur during labor late stages [2, 7, 9]. Another research team of investigators have observed and concluded that secondary meconium stained amniotic fluid is correlated to poorer neonatal clinical outcomes

involving neonatal ICU admission, raised expected clinical risk for low 5 min Apgar scoring level and umbilical artery pH below 7.1 in comparison and contrast to research controls having clear amniotic fluid [10, 14].

### Conclusions and recommendations

This research study has revealed the critical importance of meconium heavy staining of amniotic fluid to abnormal fetal heart rate denoting that it could be implemented as clinical predictability tool for fetal distress even in absence of fetal monitoring. However future research efforts are required to be multicentric in fashion with larger sample sizes to verify the current study results. Furthermore, future research efforts are required to be implemented to discriminate the clinical value of primary and secondary clinical categories of meconium stained amniotic fluid.

### References

1. Addisu D, Asres A, Gedefaw G, Asmer S. Prevalence of meconium stained amniotic fluid and its associated factors among women who gave birth at term in Felege Hiwot comprehensive specialized referral hospital, North West Ethiopia: a facility based cross-sectional study. *BMC Pregnancy Childbirth*. 2018; 18:429. <https://doi.org/10.1186/s12884-018-2056-y>
2. Hirsch L, Krispin E, Aviram A, Wiznitzer A, Yogev Y, Ashwal E. Effect of meconium-stained amniotic fluid on perinatal complications in low-risk pregnancies at term. *Am J Perinatol*. 2016; 33:378-84. <https://doi.org/10.1055/s-0035-1565989>
3. American College of Obstetricians and Gynecologists Women's Health Care Physicians (ACOG). ACOG Practice Bulletin No. 138. Inherited thrombophilias in pregnancy. *Obstet Gynecol*. 2013; 122:706-17. <https://doi.org/10.1097/01.AOG.0000433981.36184.4e>
4. Committee on Practice Bulletins-Obstetrics, American College of Obstetricians and Gynecologists. Practice Bulletin No. 132: Antiphospholipid syndrome. *Obstet Gynecol*. 2012; 120:1514-21. <https://doi.org/10.1097/01.AOG.0000423816.39542.0f>
5. American College of Obstetricians and Gynecologists, Task Force on Hypertension in Pregnancy. Hypertension in pregnancy. Report of the American College of Obstetricians and Gynecologists' Task Force on Hypertension in Pregnancy. *Obstet Gynecol*. 2013; 122:1122-31. <https://doi.org/10.1097/01.AOG.0000437382.03963.88>
6. Kehl S, Schelkle A, Thomas A, Puhl A, Meqdad K, Tuschy B, *et al*. Single deepest vertical pocket or amniotic fluid index as evaluation test for predicting adverse pregnancy outcome (SAFE trial): a multicenter, open-label, randomized controlled trial. *Ultrasound Obstet Gynecol*. 2016; 47:674-9. <https://doi.org/10.1002/uog.14924>
7. Hirsch L, Melamed N, Rosen H, Peled Y, Wiznitzer A, Yogev Y. *et al*. New onset of meconium during labor versus primary meconium stained amniotic fluid - Is there a difference in pregnancy outcome? *J Matern Neonatal Med*. 2014; 27:1361-7. <https://doi.org/10.3109/14767058.2013.858320>
8. Weiner E, Schreiber L, Grinstein E, Feldstein O, Rymer-Haskel N, Bar J, *et al*. The placental component and obstetric outcome in severe preeclampsia with and without HELLP syndrome. *Placenta*. 2016; 47:99-104. <https://doi.org/10.1016/j.placenta.2016.09.012>
9. Weiner E, Miremberg H, Grinstein E, Mizrahi Y, Schreiber L, Bar J, *et al*. The effect of placenta previa on fetal growth and pregnancy outcome, in correlation with placental pathology. *J Perinatol*. 2016; 36:1073-78. <https://doi.org/10.1038/jp.2016.140>
10. Xu H, Mas-Calvet M, Wei SQ. Abnormal fetal heart rate tracing patterns in patients with thick meconium staining of the amniotic fluid: association with perinatal outcomes. *Am J Obstet Gynecol*. 2009; 200:283e1-283.e7.
11. Gee H. Routine intrapartum care: an overview. In: Luesley DM, Baker PN. *Obstetrics and gynecology: an evidence based text for MRCOG*, 2nd edition. Hodder Arnold, 2010, 287-95.
12. NICE. Intra-partum care. Clinical Guideline 55. London: National Institute for Health and Clinical Excellence, 2007.
13. Naveen S, Kumar SV, Ritu S, Kushia P. Predictors of meconium stained amniotic fluid: a possible strategy to reduce neonatal morbidity and mortality. *J Obstet Gynecol India*. 2006; 56:514-7.
14. Shaikh EM, Mehmood S, Shaikh MJ. Neonatal outcome in meconium stained amniotic fluid- One year experience. *J Pak Med Assoc*. 2010; 60:711-4.